Research and Report

Clinical Analysis of small Acoustic neuromas With Initial Neurological Symptoms

Ke-Yang Chen1, MD; Tian Miao Sun2; Jun-Hao Fang3, MD; Si Chen4, MD; Bo-Bei Chen, MD4*

1. Department of Neurology, The Second Affiliated Hospital and Yuying Children's Hospital of Wenzhou Medical University, Wenzhou, Zhejiang, China.

2.The second school of medicine, Wenzhou Medical University

3. Department of Neurosurgery, The Second Affiliated Hospital and Yuying Children's Hospital of Wenzhou Medical University, Wenzhou, Zhejiang, China.

4. Department of Otolaryngology, The Second Affiliated Hospital and Yuying Children's Hospital of Wenzhou Medical University, Wenzhou, China

* Correspondence: Bo-Bei Chen, MD,

Department of Otolaryngology, The Second Affiliated Hospital and Yuying Children's Hospital of Wenzhou Medical University,

Address: College West Road No. 109, Wenzhou, Zhejiang 325027, China.

Email: wzbobei@126.com

Received: September 21, 2021; Accepted: September 29, 2021

Abstract

Background: To investigate and describe the clinical features of small ANs presenting with initial neurological manifestations, to allow earlier diagnosis and more well-timed interference for patients with this disease.

Methods: A retrospective cross-sectional study was performed in the Second Affiliated Hospital of Wenzhou Medical University, Zhejiang Province, China. This study was included 22 patients. The detailed clinical information with initial symptoms of neurological manifestations caused by small ANs between January 2010 and May 2020 were retrospectively analyzed. The collected data included symptoms, signs, neuroimaging results, and pathologic diagnoses.

Results: There were 9 males and 13 females, and their ages ranged from 22 to 74 years. Dizziness/vertigo was the most common initial presenting symptom in 9 of the 22 patients.

Correspondence author:
Bo-Bei Chen, MD
Professional title: Professor
Research direction: Children's otolaryngology
The Second Affiliated Hospital and Yuying Children's Hospital of Wenzhou Medical University

Headache was the second most frequent initial presenting symptom in 8 of 22. Neuro-physical examination found that the facial nerve and auditory nerve were the most involved cranial nerves, with remaining positive signs involving abnormalities of the optic nerve, trigeminal nerve and abducens nerve as well as ataxia and nystagmus. More than half of the patients underwent microsurgery and had postoperative clinical symptom improvement. The patients who chose the observation method showed no change in tumor size at follow-up.

Conclusions: Dizziness/vertigo and headache are the most common initial neurological symptoms of small ANs and should be considered in the differential diagnosis of patients. The results suggest that MRI is the best tool in diagnosis for small ANs. Observation and microsurgery are safe and common methods for the treatment.

Key words: Acoustic neuromas, nervous system, early stage, diagnosis, Retrospective study

Background

Acoustic neuromas (ANs), or vestibular schwannomas, which were first identified in 1777 by Eduard Sandifort [1], represent a type of benign brain tumor of Schwann cells that mostly arises from the vestibular nerve [2]. ANs represent one of the most common intracranial tumors with an incidence from 1 to 20 per million, and ANs accounts for approximately 6% of all intracranial tumors [3]. Additionally, the incidence of acoustic neuromas is slightly increasing worldwide [4, 5]. In the cerebellopontine angle (CPA) area, facial (VI), acoustic and vestibular (VIII) nerves run across it to the internal auditory meatus, and the trigeminal (V) nerve is located at the apex of the cerebellopontine angle. The base region of the cerebellopontine angle contains the lower cranial nerves (IX, X, and XI) [6]. Consequently, the initial symptoms of ANs are often vague and imperceptible, especially in cases of small tumors. The general inspection offers little diagnostic information, resulting in misdiagnosis and mistreatment. Unilateral progressive hearing loss is the most common initial symptom of ANs, but ANs may have other uncharacteristic presentations. As a result of the atypical neurological presentations, patients are inclined to consult in neurology departments. Neurological symptoms may be caused by ANs compressing the brainstem or by raised intracranial pressure in the cerebellopontine angle. It is vital to

detect, diagnose and treat small ANs at an early stage. We retrospectively investigated the clinical features of small ANs, primarily focusing on those with initial neurological symptoms, to improve awareness of the disease among neurologists.

Methods

Study Design and Setting

A retrospective cross-sectional study was performed in the Second Affiliated Hospital of Wenzhou Medical University, Zhejiang Province, China. Approval was obtained from the Institutional Review Board and Ethics Committee of the Second Affiliated Hospital of Wenzhou Medical University. Written informed consent to participate in this study was provided by the patients and participants' legal guardian/next of kin.

Study Participants and Data Source

Data were collected after review of the electronic medical records of all patients who initially presented to the neurology department and then were treated by the otolaryngology or neurosurgery department of the Second Affiliated Hospital of Wenzhou Medical University from January 2010 to January 2020.

Variables and Measures

Two investigators independently used the term "Acoustic neuromas (ANs)" or "Vestibular schwannomas" or a diagnosis code in the International Classification of Diseases, 10th edition, Clinical Modification of D33.3 in the electronic medical record discharge registration to obtain the basic information of patients who had presented with neurological symptoms and who were diagnosed with ANs. The following detailed information was extracted: age, sex, residential status, admission time, visit history, initial symptoms, clinical manifestations, type of treatment, discharge status, personalized medication, radiologic examination, postoperative complications and follow-up records. Patients with stage 1 (in the internal auditory meatus) or 2 (in the internal auditory meatus and cerebellar pontine angle without contact with the brainstem) Koos classification [7] were included, based on each patient's initial magnetic resonance imaging (MRI) scan. Tumor size was measured with the longest diameter (mm) in the CPA [8] and classified according to the 1995 American Academy of Otolaryngology-Head and Neck Surgery guidelines [9]. Disagreements were resolved through consultation with a third experienced-investigator (CBB).

The exclusion criteria were patients who had type 2 neurofibromatosis, Koos classification 3 or 4, and patients with incomplete or unavailable medical records as well as patients without follow-up records.

Statistical Analysis

No statistical inferences were conducted in this study. The proportion of clinical symptoms to the total was presented as percentages. Microsoft Excel was used to assist in gathering the data.

Results

We retrieved medical records, and a total of 102 patients were diagnosed with ANs during the study period. Patients in whom the initial symptoms were non-neurological manifestations (n=63), Koos classification 3 or 4 (n=6), and patients with a pathological diagnosis of another tumor (n = 6), missing follow-up records or incomplete clinical data (n =5) were excluded, resulting in a total of 22 patients. Figure 1 demonstrates the sample inclusion and exclusion criteria. Overall, patients were aged from 22 to 74 years, with an average age of 53.5±13.2 years (Table 1), and 8 had ANs on the left side and 14 on the right side. The symptomatology was usually nonspecific and the average lag time for the diagnosis of ANs was (11.06 ±11.27) months. Table 2 revealed that dizziness/vertigo was the most frequent initial neurological symptom (9/22), and headache was the second most common neurological symptom in our study (8/22) (One patent's initial presenting symptom was both dizziness and headache), occurring in the form of frontal, occipital, intermittent-throbbing or paroxysmal headache. The third most common initial neurological symptom was facial symptoms, such as numbness and pain. The remaining initial neurological symptoms included walking problems. The total clinical symptoms of the 22 patients accompanied by 6 cases of hearing loss, 7 cases of ear symptoms (5 tinnitus,1 aural fullness,1 deafness) and 3 cases of visual disturbances (Table 3). Upon neurological examination, 2 patients had optic nerve palsy, 1 had trigeminal nerve abnormalities, 1 had abducens nerve palsy, 4 had facial nerve abnormalities, 5 had auditory nerve abnormalities, 1 had ataxia, and 2 had nystagmus. The remaining 9 patients of the total 22 had a normal neurological examination in this study. With regard to the imaging scans,4 subjects had only CT scans of the brain, 6 had MRI only scans, and 12 underwent both CT and MRI scans. In our study, all of the patients underwent MRI to detect the

extension of ANs during the follow-up. Seven patients in our study experienced surgery via the translabyrinthine approach, 6 underwent craniotomy via the retrosigmoid approach, and 8 underwent observation. One patient underwent surgery via a left suboccipital approach.

Representative Case

An elderly nondiabetic patient with a history of hypertension presented with one year of shooting pain attacks on the left side of the face. The patient's accompanying symptoms included vertigo and neuralgia without hearing loss or tinnitus for 8 months. The pain attacks were typically sudden, acute, and short, and they occurred along the trigeminal nerve path. The patient was first diagnosed with prosopalgia and migraine successively and was seen about these six times for nearly one year in a neurology clinic. Clinical examination revealed a pulse of 69/min and a blood pressure of 168/85 mm Hg. The patient's pain was measured by the visual analogue scale and was scored as grade 6. Neurological examination showed round, regular, equal pupils and sensitivity upon light reflex testing. Cranial nerve examination was negative as well as the Romberg test (-) and Heel-knee-tibia test (-). Initially, the proposed treatment was to reduce pain using 20 mg carbamazepine twice a day. In the follow-up period, the symptoms were alleviated slightly but still occurred continuously. A neurologist who supervised the case proposed an imaging examination. Mastoid CT: the left internal auditory canal was slightly widened compared with the normal meatus on the right (Figure 2). MRI revealed a round mass with a size of 1.3 × 1.0 cm in the left CPA region (Figure 3). The lesion was hypointense on T1-weighted imaging (T1WI) and unevenly hyperintense on T2-weighted imaging (T2WI). Heterogeneous enhancement of the tumor was observed with contrast-enhanced MRI. Furthermore, the results of ocular vestibular-evoked myogenic potential (o-VEMP) and cervical vestibular-evoked myogenic potential (c-VEMP) testing implied that the balloon-vestibular pathway was abnormal. The videonystagmograph (VNG) test revealed decreases in left vestibular function (Figure 4). Pure tone audiometry [10] revealed severe left and middle right sided sensorineural hearing loss (SNHL) and the Distortion Product Otoacoustic Emissions (DPOAEs) of the left ear revealed no responses in any frequency areas (Figure 5).

An acoustic immittance showed a binaural C curve, and the left ear speech discrimination score (SDS) was 0% at both 90 db and 100 db. After transfer to the ear, nose and throat (ENT) department, the patient underwent surgery via the translabyrinthine approach. The pathological examination results suggested an acoustic neuroma on the left side of the cerebellopontine angle. At the 6-month follow-up, the patient reported no further pain attacks.

Discussion

Acoustic neuromas are the most common type of tumor in the region of the internal auditory canal with a higher prevalence in females than in males [3]. Our study found the same trend, with a larger prevalence of ANs in women (n = 59.1%) than in men (n = 40.9%). Dizziness is a shared complaint among patients presenting to primary care physicians, accounting for 30% of people suffering at different points [11]. In AN patient, vertigo strongly influences quality of life. The true incidence of vertigo in the AN patient population is controversial, from 10%--70% [12-14]. In our practice, vertigo is present in 41% of patients at baseline. When these patients consult in the neurology department, they are commonly first diagnosed with peripheral vestibular vertigo, such as benign paroxysmal positional vertigo, Meniere's disease, or persistent postural-perceptual dizziness. Furthermore, ANs can cause secondary hydrocephalus and vestibular changes, which can result in vertiginous episodes. However, we found that it is difficult to observe or detect vestibular abnormalities. The average lag time for diagnosis is 11.06 ±11.27 months. A previous study suggested that tumor size may be associated with the severity of vertigo [15]. Because ANs grow slowly and undergo sensory substitution, there is adequate time for the occurrence of vestibular compensation and adjustment. In addition, some have argued that the symptom of dizziness is related to patient age [16, 17]. Nilsen.et.al explained that central compensation leads to a slight decrease in dizziness over time in patients with diagnosed AN and counteracts the effects of aging [18]. It is vital to detect vestibular dysfunction at the early stage of AN. In patients with non-specific vertigo, unexplained unilateral VHIT and VEMP asymmetry should alert neurologists to perform imaging [12].

Headache is among the most common causes in patients seeking medical attention in neurology departments.

Headache resulting from acoustic neuromas generally belongs to the category of secondary headache. To date, most studies have focused on headaches after surgery, including microsurgical resection and retrosigmoid craniotomy [19-21]. Despite the connection between headache in patients with ANs and substantial physical and emotional burdens, this condition remains unnoticed. One study discovered that the prevalence of headache in patients was surprisingly 60%, with varying degrees of headache before treatment, and 19% recorded a positive history of migraine [22]. RyzenHman and colleagues suggested that headache was the second most common symptom in 17.6% of patients with small tumors [23]. In our study, headache was also the second most common neurological symptom in AN patent who consulted in the neurology department. Acoustic neuromas generally do not cause headaches until they are large enough to compress the fifth cranial nerve or until they cause obstructive hydrocephalus resulting from fourth ventricle effacement. Mechanisms of headache caused by small ANs include increased intracranial pressure, venous outflow obstruction, and pain associated with dura sensitivity or meningeal vasculature as well as intracranial sensory nerves such as the trigeminal nerve, facial nerve, glossopharyngeal nerve, and vagus nerve [24]. Another explanation for headache is dural traction within the internal auditory canal. In terms of neuroanatomical observations of the trigeminal system, C2 and C3 projections are to the ventral posteromedial nucleus rather than to the ventral posterolateral nucleus, leading to headaches with occipital origin extending to the V1 distribution [25]. The condition is often misdiagnosed as migraine, trigeminal neuralgia, or tension headache due to the different potential presentations of ANs; for example, there have been 5 cases where patients report that they were misdiagnosed with migraine, 1 case was tension headache.

Imaging is a crucial tool in the evaluation, treatment and management of patients with ANs, including magnetic resonance imaging (MRI) imaging and computerized tomography (CT). A previous study suggested that if the hearing threshold is worse than 70 dB, patient management should directly proceed to CT [26]. However, MRI with gadolinium enhancement is now widely accepted as the 'gold standard' inspection for acoustic neuromas [27]

because it is superior for identifying soft-tissue structures, whereas CT can provide resolution of bone structures and detect moderate-large ANs. A further advantage of using MRI as the primary screening procedure is its ability to identify small tumors [28]. T1-weighted sequences of mucoceles reveal hypo intensity of the mass, whereas T2-weighted sequences show equal intensity or hyperintensity with significant enhancement. Some MRIs reveal a high signal intensity on both T1-weighted sequences and T2-weighted sequences because of the associated bleeding. Enhanced MRI scans show the most uneven patchy enhancement and ipsilateral auditory nerve thickening and strengthening, which are characteristics of neoplastic processes [29]. Therefore, MRI was the best diagnostic and detection method in our cohort study.

Three treatment options are available for AN patient: observation, radiotherapy (RT) and microsurgery (MS) via hearing preservation retrosigmoid or middle fossa approach or trans-labyrinthine approach. The choice of treatment depends on several criteria such as age, comorbidity, tumor size and location, hearing status, expected treatment outcomes and complications, and patient preference. For small ANs, especially in elderly patients, the “wait and see” controlling method has been advised [30]. The appropriate and proactive option for patients who hope for hearing preservation is microsurgery [31] or rehabilitation with translabyrinthine surgery and hearing aids. Multi-option management for small ANs has been found to be an effective strategy in terms of hearing outcomes [32].

We recognize some limitations of this study. First, our study is a retrospective data analysis. All relevant information was documented from electronic medical records. Second, the investigation lacked complete information about the exact neurological outcomes because the patients were discharged from the Department of Otolaryngology or Neurosurgery, and they did not have a routine neurological examination. Furthermore, the follow-up time was not long enough to obtain the terminal outcomes, and some patients who underwent the “wait-and-see” did not continue follow-up to identify the delayed treatment.

Conclusions

Although the majority of patients with acoustic neuromas present with classic, progressive, unilateral hearing loss, the neurological symptoms of ANs are

becoming more universal. As our findings confirmed, these atypical initial neurological symptoms are more frequent in small lateral neuromas.

Neurologists must consider the possibility of AN when patients with other etiologies of headache, vertigo, and facial symptoms and especially hearing loss and tinnitus present to the neurology department or neurological emergency department. The next step is referral to the ENT or neurosurgery department for investigative imaging and audiological examination. Therefore, a better understanding of this disease by neurologists, as well as otolaryngologists and neurosurgeons is essential for early diagnosis and prompt surgical treatments in order to avoid misdiagnosis and mistreatment.

Acknowledgements

We would like to thank the study participants and the research assistants for actively participating.

Ethics statement

Conflict of interest: The authors declare that there is no conflict of interest.

Ethical approval: Approval was obtained from the Institutional Review Board and Ethics Committee of the Second Affiliated Hospital of Wenzhou Medical University and with the 1964 Helsinki declaration and its later amendments or comparable ethical standards.

Authors' contributions: BB.C and KY.C are the main authors designed and distribution as well as data collation and analysis; Data Curation, S.C,JH.F ; riting—Original Draft, KY.C ; TM.S; Writing—Review &Editing KY.C ;Supervision, BB.C and KY.C

References

[1] Gibson, G.A., Remarks on the Results of Surgical Measures in a Series of Cerebral Cases. Transactions. Medico-Chirurgical Society of Edinburgh, 1896. 15: p. 27-46.

[2] A, W. and B. R, Management of acoustic neuroma. BMJ : British medical journal / British Medical Association, 1995. 311(7013): p. 1141-4.

[3] Chen M, Fan Z, Zheng X, Cao F, Wang L. Risk Factors of Acoustic Neuroma: Systematic Review and Meta-Analysis. Yonsei Med J. 2016;57(3):776-783. doi:10.3349/ymj.2016.57.3.776

[4] Babu R, Sharma R, Bagley JH, Hatef J, Friedman AH, Adamson C. Vestibular schwannomas in the modern era:

epidemiology, treatment trends, and disparities in management. J Neurosurg. 2013;119(1):121-130. doi:10.3171/2013.1.JNS121370

[5] Reznitsky M, Petersen MMBS, West N, Stangerup SE, Cayé-Thomasen P. Epidemiology Of Vestibular Schwannomas - Prospective 40-Year Data From An Unselected National Cohort. Clin Epidemiol. 2019;11:981-986. Published 2019 Nov 8. doi:10.2147/CLEP.S218670

[6] Wright A, Bradford R. Management of acoustic neuroma. BMJ. 1995;311(7013):1141-1144. doi:10.1136/bmj.311.7013.1141

[7] Koos WT. Criteria for preservation of vestibulocochlear nerve function during microsurgical removal of acoustic neurinomas. Acta Neurochir (Wien). 1988;92(1-4):55-66. doi:10.1007/BF01401974

[8] Kanzaki, J. , Tos, M. , Sanna, M. , & Moffat, D. A. . (2003). New and modified reporting systems from the consensus meeting on systems for reporting results in vestibular schwannoma. Otology & Neurotology, 24(4), 642-649.

[9] Committee on Hearing and Equilibrium guidelines for the evaluation of hearing preservation in acoustic neuroma (vestibular schwannoma). American Academy of Otolaryngology-Head and Neck Surgery Foundation, INC. Otolaryngology--head and neck surgery : official journal of American Academy of Otolaryngology-Head and Neck Surgery, 1995. 113(3): p. 179-180.

[10] Kataria R, Gupta S, Chopra S, Bagaria H, Sinha VD. Mucocele of the sphenoid sinus: A rare cause of reversible 3(rd) nerve palsy. Ann Indian Acad Neurol. 2012;15(2):158-160. doi:10.4103/0972-2327.95006

[11] Karatas M. Central vertigo and dizziness: epidemiology, differential diagnosis, and common causes. Neurologist. 2008;14(6):355-364. doi:10.1097/NRL.0b013e31817533a3

[12] Taylor RL, Kong J, Flanagan S, et al. Prevalence of vestibular dysfunction in patients with vestibular schwannoma using video head-impulses and vestibular-evoked potentials. J Neurol. 2015;262(5):1228-1237. doi:10.1007/s00415-015-7697-4

[13] Kentala E, Pyykkö I. Clinical picture of

vestibular schwannoma. Auris Nasus Larynx. 2001;28(1):15-22. doi:10.1016/s0385-8146(00)00093-6

[14] Humphriss, R. , Baguley, D. , Axon, P. , & Moffat, D. . (2006). Preoperative audiovestibular handicap in patients with vestibular schwannoma. Skull Base, 16(4), 193-199.

[15] Wagner JN, Glaser M, Wowra B, Alexander Muacevic, Roland Goldbrunner, Christian Cnyrim, Jörg-Christian Tonn, Michael Strupp. Vestibular function and quality of life in vestibular schwannoma: does size matter?. Front Neurol. 2011;2:55. Published 2011 Aug 30. doi:10.3389/fneur.2011.00055

[16] Saman Y, Bamiou DE, Murdin L, K Tsioulos , Rosalyn Davies , Mayank BD , Rupert Obholzer, Michael Gleeson . Balance, falls risk, and related disability in untreated vestibular schwannoma patients. J Neurol Surg B Skull Base. 2014;75(5):332-338. doi:10.1055/s-0034-1372469

[17] Du Pasquier RA, Blanc Y, Sinnreich M, Landis T, Burkhard P, Vingerhoets FJ. The effect of aging on postural stability: a cross sectional and longitudinal study. Neurophysiol Clin. 2003;33(5):213-218. doi:10.1016/j.neucli.2003.09.001

[18] Nilsen KS, Lund-Johansen M, Nordahl SHG, Finnkirk M, Goplen FK. Long-term Effects of Conservative Management of Vestibular Schwannoma on Dizziness, Balance, and Caloric Function. Otolaryngol Head Neck Surg. 2019;161(5):846-851. doi:10.1177/0194599819860831

[19] Schaller B, Baumann A. Headache after removal of vestibular schwannoma via the retrosigmoid approach: a long-term follow-up-study. Otolaryngol Head Neck Surg. 2003;128(3):387-395. doi:10.1067/mhn.2003.104

[20] Golub JS, Weber JD, Leach JL, et al. Feasibility of the Ultrasonic Bone Aspirator in Retrosigmoid Vestibular Schwannoma Removal. Otolaryngol Head Neck Surg. 2015;153(3):427-432. doi:10.1177/0194599815587485

[21] Sabab A, Sandhu J, Bacchi S, Jukes A, Zacest A. Postoperative headache following treatment of vestibular schwannoma: A literature review. J Clin Neurosci. 2018;52:26-31. doi:10.1016/j.jocn.2018.04.003

[22] Carlson ML, Tveiten ØV, Driscoll CL, et al. Risk factors and analysis of long-term headache in sporadic vestibular schwannoma:

a multicenter cross-sectional study. J Neurosurg. 2015;123(5):1276-1286. doi:10.3171/2014.12.JNS142109

[23] Ryzenman JM, Pensak ML, Tew JM Jr. Patient perception of comorbid conditions after acoustic neuroma management: survey results from the acoustic neuroma association. Laryngoscope. 2004;114(5):814-820. doi:10.1097/00005537-200405000-00005

[24] Cohen JM. Teaching case: meningioma as the cause of daily headache?. Headache. 2009;49(4):627-630. doi:10.1111/j.1526-4610.2009.01386.x

[25] Poletti, C. E. . (1992). C2 and c3 radiculopathies anatomy, patterns of cephalic pain, and pathology. APS Journal, 1(4), 272-275.

[26] Swan IR, Browning GG. Imaging patients with suspected acoustic neuroma. Lancet. 1989;1(8631):219. doi:10.1016/s0140-6736(89)91232-4

[27] Robson AK, Leighton SE, Anslow P, Milford CA. MRI as a single screening procedure for acoustic neuroma: a cost effective protocol. J R Soc Med. 1993;86(8):455-457.

[28] Modugno GC, Pirodda A, Ferri GG, et al. Small acoustic neuromas: monitoring the growth rate by MRI. Acta Neurochir (Wien). 1999;141(10):1063-1067. doi:10.1007/s007010050483

[29] House JW, Bassim MK, Schwartz M. False-positive magnetic resonance imaging in the diagnosis of vestibular schwannoma. Otol Neurotol. 2008;29(8):1176-1178. doi:10.1097/MAO.0b013e318187e199

[30] Thedinger BA, Cueva RA, Glasscock ME 3rd. Treatment of an acoustic neuroma in an only-hearing ear: case reports and considerations for the future. Laryngoscope. 1993;103(9):976-980. doi:10.1288/00005537-199309000-00006

[31] Peng KA, Wilkinson EP. Optimal outcomes for hearing preservation in the management of small vestibular schwannomas. J Laryngol Otol. 2016;130(7):606-610. doi:10.1017/S0022215116007969

[32] Zanoletti E, Cazzador D, Faccioli C, et al. Multi-option therapy vs observation for small acoustic neuroma: hearing-focused management. Acta Otorhinolaryngol Ital. 2018;38(4):384-392. doi:10.14639/0392-100X-1756

Figure legends

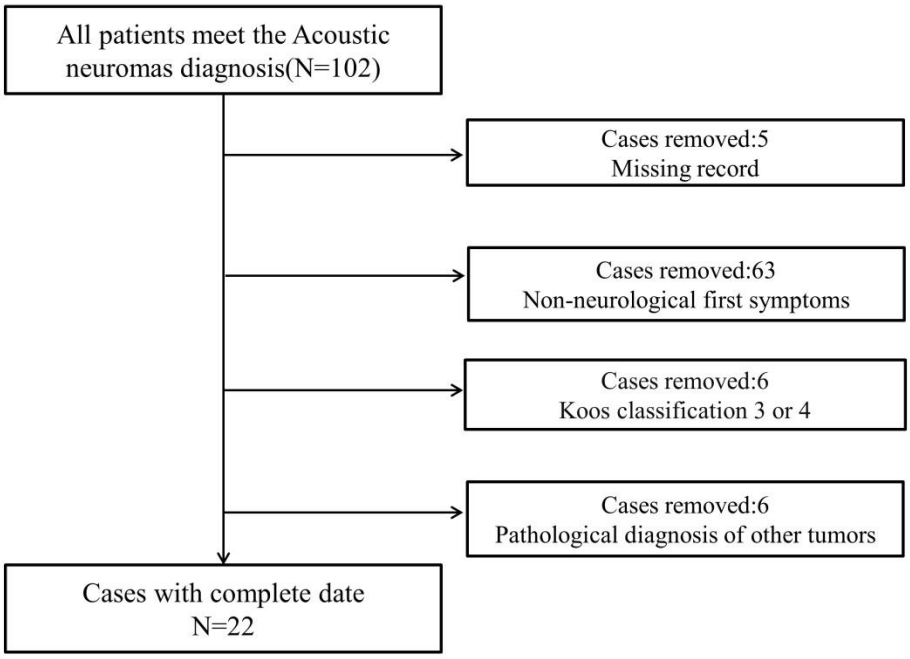

Figure 1: Flow chart of sample inclusion and exclusion

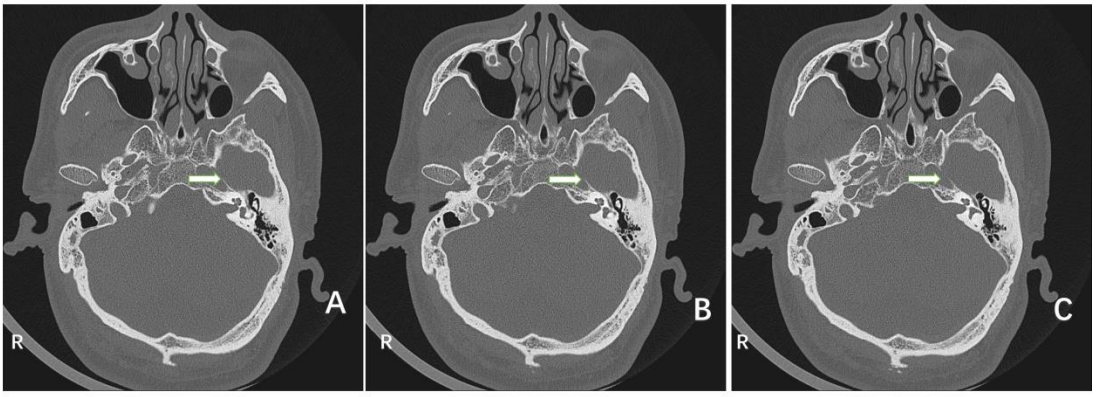

Figure 2: A, B, C: Mastoid CT taken before MRI. The left internal auditory canal is lightly widened(arrows) compared with the normal meatus on the right.

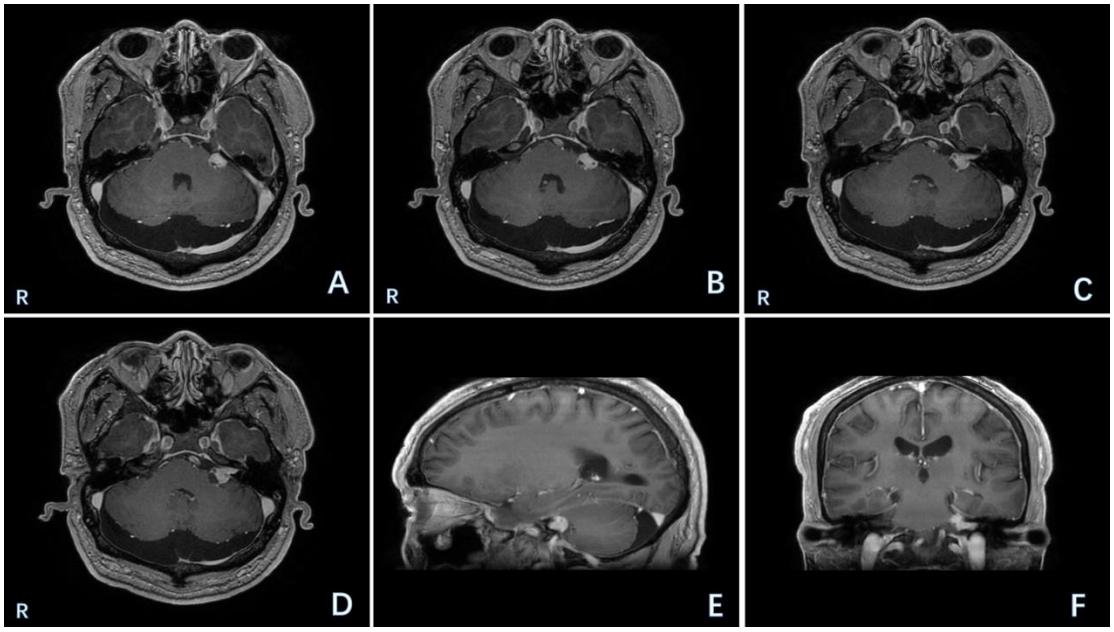

Figure 3： MRI showing a round mass with a size of 1.3 × 1.0 cm in the left CPA region. A-D: axial view, E： sagittal view, F: coronal view.

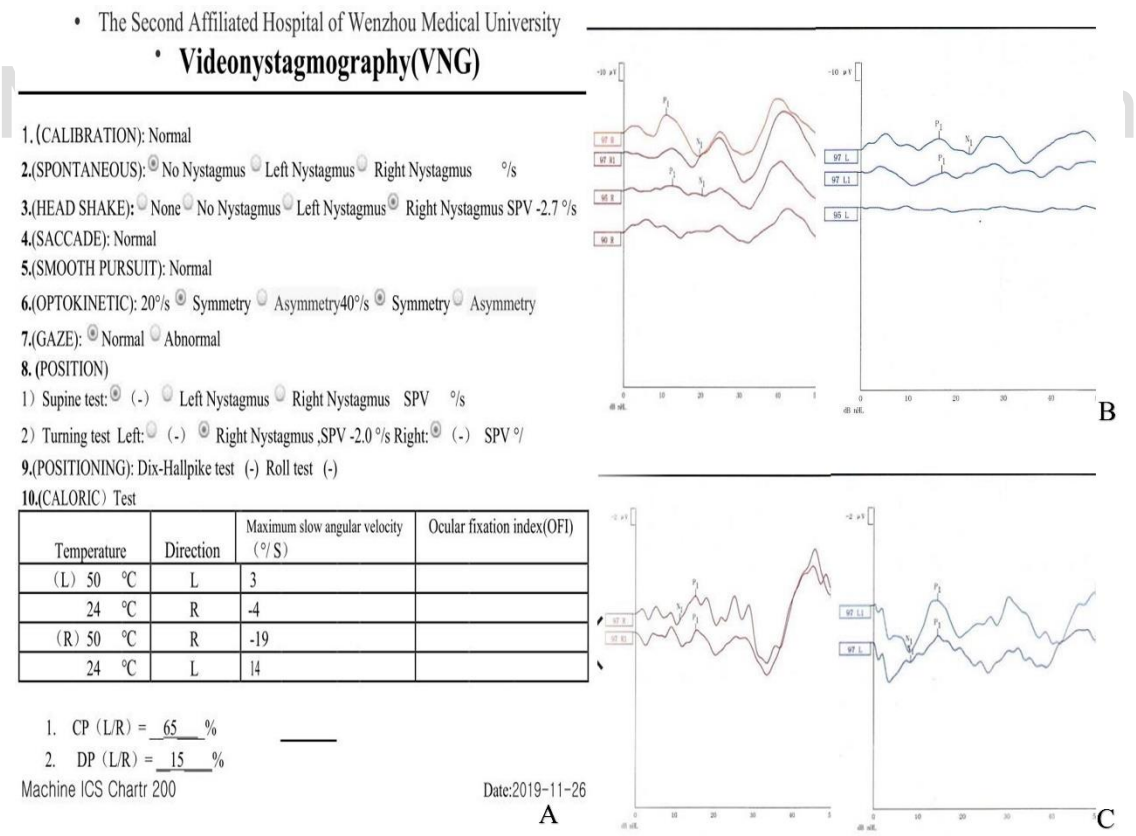

• The Second Affiliated Hospital of Wenzhou Medical University

• Videonystagmography(VNG)

1.(CALIBRATION): Normal
2.(SPONTANEOUS): ◉ No Nystagmus ○ Left Nystagmus ○ Right Nystagmus °/s
3.(HEAD SHAKE): ○ None ○ No Nystagmus ○ Left Nystagmus ◉ Right Nystagmus SPV -2.7 °/s
4.(SACCADE): Normal
5.(SMOOTH PURSUIT): Normal
6.(OPTOKINETIC): 20°/s ◉ Symmetry ○ Asymmetry40°/s ◉ Symmetry ○ Asymmetry
7.(GAZE): ◉ Normal ○ Abnormal
8. (POSITION)
1) Supine test: ◉ (-) ○ Left Nystagmus ○ Right Nystagmus SPV °/s
2) Turning test Left: ○ (-) ◉ Right Nystagmus ,SPV -2.0 °/s Right: ◉ (-) SPV °/
9.(POSITIONING): Dix-Hallpike test (-) Roll test (-)
10.(CALORIC) Test

Temperature	Direction	Maximum slow angular velocity (°/S)	Ocular fixation index(OFI)
(L) 50 ℃	L	3	
24 ℃	R	-4	
(R) 50 ℃	R	-19	
24 ℃	L	14	

1. CP (L/R) = 65 %
2. DP (L/R) = 15 %

Machine ICS Chartr 200 Date:2019-11-26

A

B

C

Figure4: A. Videonystagmography showed right eye nystagmus in head-shaking test and left vestibular function descent in caloric test. B: c-vemp showed that a

left-right amplitude ratio is about 0.45 in 97dBnHL threshold. C: o-vemp showed that a left-right amplitude ratio is about 0.36 in 97dBnHL threshold.

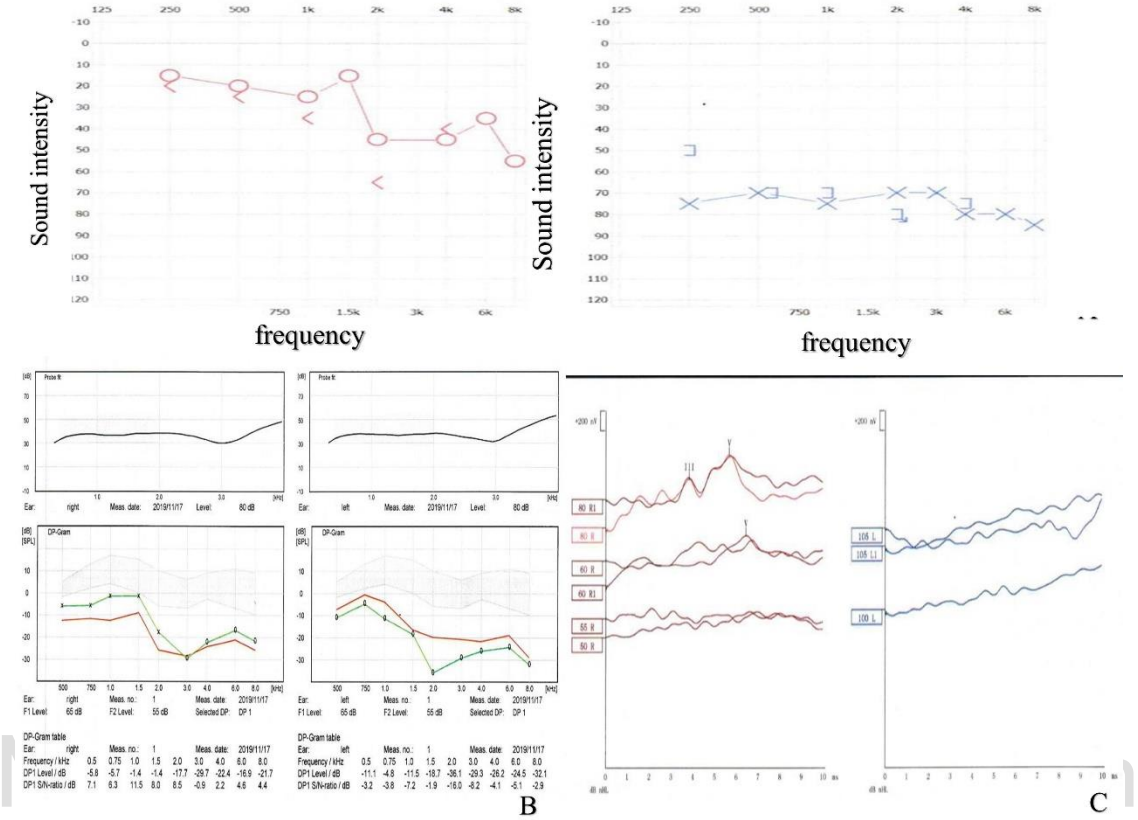

Figure 5: A. Pure tone audiometry revealed severe left and middle right sided sensorineural hearing loss (SNHL); B. The Distortion Product Otoacoustic Emissions of left ear revealed no responses in any frequency areas; C. click-ABR showed that the right ear 60db but the left was no in 105dB.

Table 1.—Clinical Information in Patients With ANs With Initial Neurological Symptoms

No.	Age	Presenting neurological Symptoms	Initial Diagnosis	Radiologic Finding	Treatment	Treatment Time in Neurology
1	37	Dizziness 4 for years and progressive hearing loss for 3 years	Meniere's disease	CT: right cerebellopontine angle cystic space occupying with hemorrhage	Retrosigmoid approach craniotomy	3 years
2	58	Episodic dizziness for 2 years	BPPV	MRI: occupied lesions in CPA (R)	Retrosigmoid approach craniotomy	1.5 years
3	39	Left facial numbness for 1 year	Bell's palsy	CT: occupied lesions in CPA (L) MRI: occupied lesions in CPA (L)	Translabyrinthine (TL) approach surgery	10 months
4	45	Right paroxysmal headache with blurred vision for 2 weeks	Migraine	MRI: occupied lesions in CPA (R)	Translabyrinthine (TL) approach surgery	1 week
5	68	Dizziness for 2 years	Anxiety	MRI: occupied lesions in	Observation	2 years

				CPA(R)		
6	67	Ptosis for 9 months	Diabetic peripheral neuropathy	MRI: occupied lesions in CPA(L)	Translabyrinthine (TL) approach surgery	0.5 years
7	49	Dizziness for 4 years	Persistent Postural-Perceptual Dizziness	Enhanced MRI: right cerebellopontine angle lesions abnormality signal, equal signals on T1WI, T2WI	Observation	3.5years
8	62	Right-sided intermittent-throbbing headache for 11 months	Migraine	MRI: right cerebellopontine angle lesion, adjacent to the internal acoustic, ANs?	Observation	10 months
9	65	Dizziness and headache for 2 years	Vestibular migraine	CT left occupied lesions in CPA MRI: left occupied lesions in CPA	Retrosigmoid approach craniotomy	1.6 years
10	57	Paroxysmal facial numbness for 2 months	Transient Ischemic Attack	CT: left occupied lesions in CPA MRI: left occupied lesions in CPA	Observation	1 month
11	41	Dizziness for 4 months	BPPV	CT: left Occupied lesions in CPA	Translabyrinthine (TL) approach surgery	4 months
12	69	Walking instability with blurred vision for one year	Posterior circulation ischemia	CT: right cerebellopontine angle with ipsilateral internal auditory canal enlargement	Translabyrinthine (TL) approach surgery	9 months
13	56	Vertigo and vomiting of sudden onset for 2 days	Hemorrhage	CT: a slightly low-density right cerebellopontine mass, enhancing with intravenous contrast medium. MR: low signa in T1-weighted. T2-weighted images its signal was eterogeneous with peripheral high signal and central low signal	Retrosigmoid approach craniotomy	1 day
14	74	Dizziness and weakness for half a year	Posterior circulation ischemia	CT: right Occupied lesions in CPA ANs?	Observation	5 months
15	47	Posterior occipital headache for 4 years, unstable gait for half a year	Occipital neuralgia	CT: left occupied lesions in CPA MRI: left occupied lesions in CPA	Observation	1 year
16	58	Shooting pain attacks on the left side of the face for 1 year	Prosopalgia	CT: left internal auditory canal is lightly widened. MRI: a slight disk displacement, with a decrease on the left side and an extensive tumoral lesion in the right acoustic channel stretching to cerebellopontine angle	Translabyrinthine (TL) approach surgery	11 months
17	53	Right facial droop for 2 months	Bell's palsy	MRI: T1WI reveal hypointensity of the mass, whereas T2WI show hyperintensity signal(R)	Observation	1.2months
18	57	Headache for one week	Hemorrhage	MRI: a high signal intensity area with a few low intensity areas. T2WI showed the mass as low intensity(R).	Operation using a left suboccipital approach	1 day
19	60	Paroxysmal pulsatile headache for half a year	Migraine	MRI: acoustic neuroma of cranial nerve VIII. T2-weighted frontal image shows high signal mass in right cerebellopontine angle compressing the brainstem	Retrosigmoid approach craniotomy	6 months
20	32	Repeated headache for half a year, aggravating for 10 days	Migraine	MRI: left occupied lesions in CPA	Retrosigmoid approach craniotomy	1 year
21	22	Recurrent frontal headache for one year	Tension headache	CT and MRI: the expansion of the right internal auditory. right occupied lesions in CPA.	Translabyrinthine (TL) approach surgery	10 months

22	61	Right mouth deviation for 9 months	Peripheral facial paralysis	MRI: right occupied lesions in CPA	Observation	8 months

Table 2.—Initial Neurological symptoms of the acoustic neuroma

Symptoms	Number	Percentage %
Vertigo	9	41
Headache	8	36
Migraine	5	23
Tension headache	1	4.5
unclassified	2	9
Facial symptom	4	18
numbness	2	9
pain	1	4.5
paralysis	1	4.5
Walking problem	1	4.5

Table 3. —Clinical symptoms of the total patients with acoustic neuromas

Symptoms	Number	Percentage %
Dizziness	10	45
Headache	8	36
Hearing loss	6	27
Facial symptom	5	23
Taste impairment	1	4.5
Tinnitus	5	23
Aural fullness	1	4.5
Blurred vision/ptosis	2	9
Deafness	1	4.5
Walking problems	2	9